



KYOCERA Medical Technologies, Inc.

ReBOSSIS[®]

Case Study 2

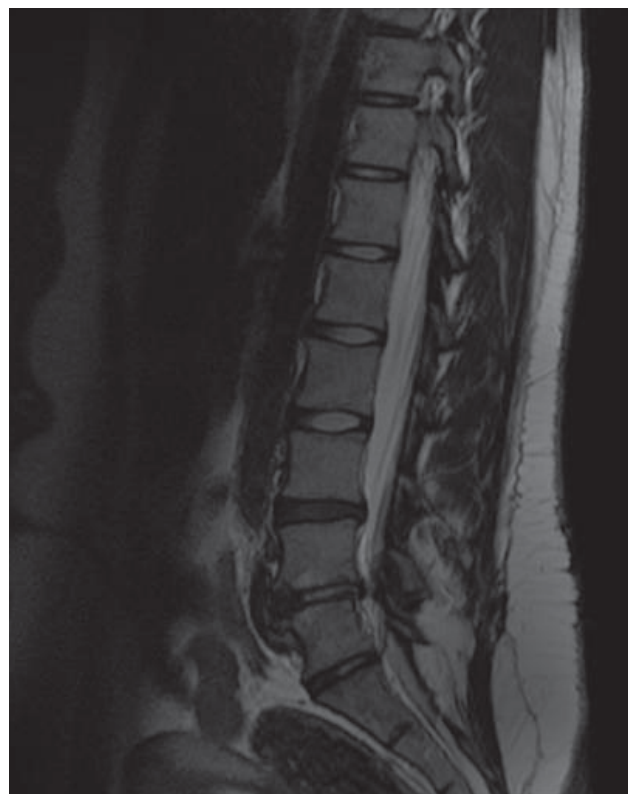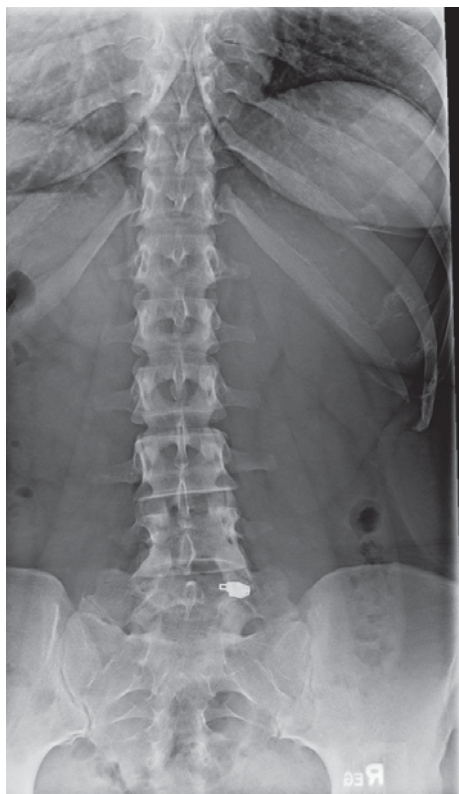TAKE A CLOSER LOOK



Not approved by the FDA for the above indication.

PATIENT PROFILE

- 27-year-old female
- Prior decompression L5—S1 (partially lumbarized S1)
- Two-year history of recurrent back pain (VAS score 9/10) and leg pain (VAS score 8/10)



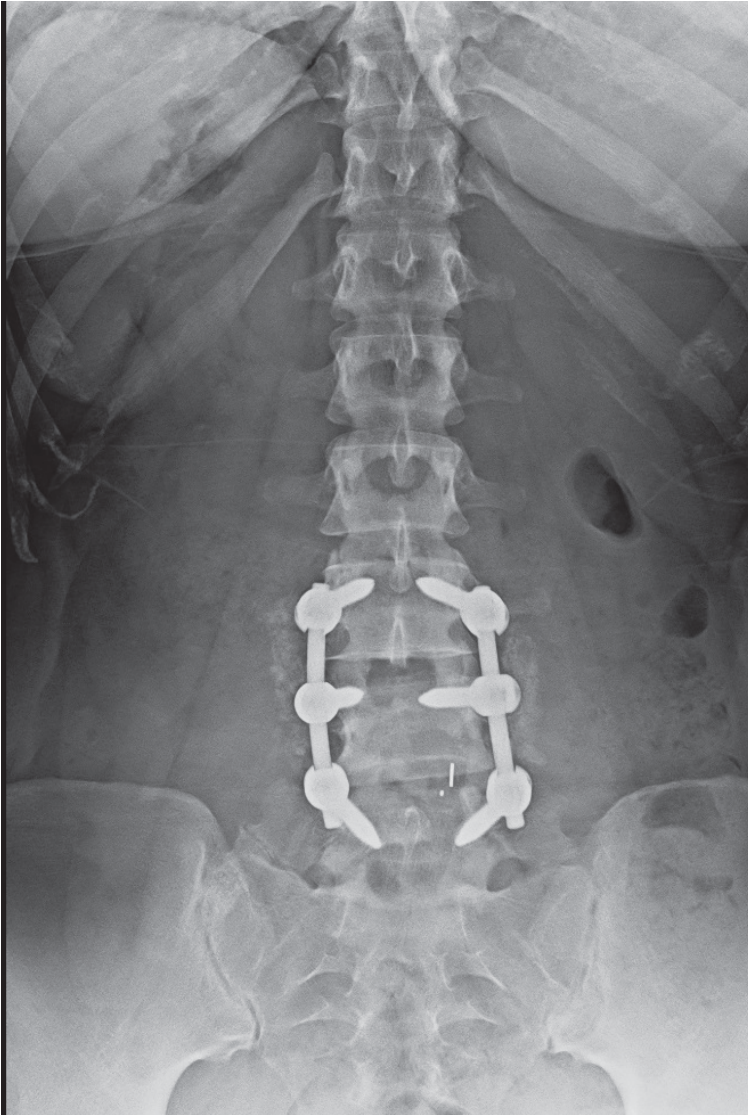
TREATMENT

- Disc space prepared in usual fashion
- 25cc ReBOSSIS® hydrated with 8cc concentrated bone marrow aspirate
- Packed into disc space after disc preparation and prior to cage placement

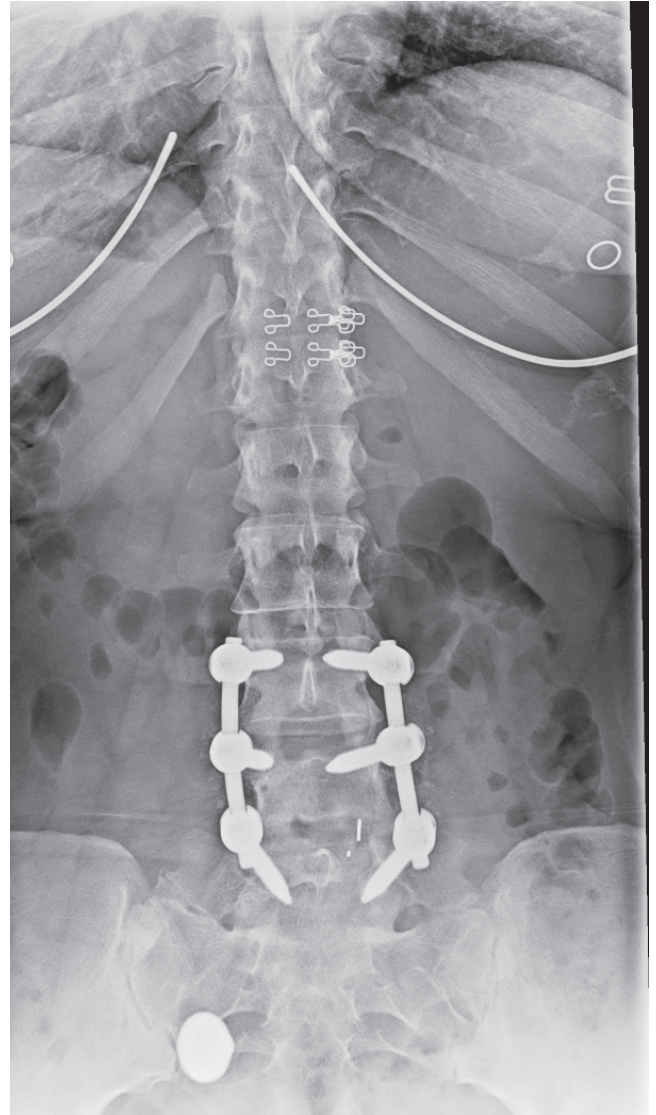


POSTOPERATIVE COURSE

- Abundant bone growth around the cage



2 weeks postop: Early healing



12 weeks postop: Bridging ossification

SURGEON PROFILE

Geoffrey Stewart, MD
Spine and Scoliosis Center
Orlando, FL

